



ASSOCIATION DE RYTHMOLOGIE
INTERVENTIONNELLE & STIMULATION

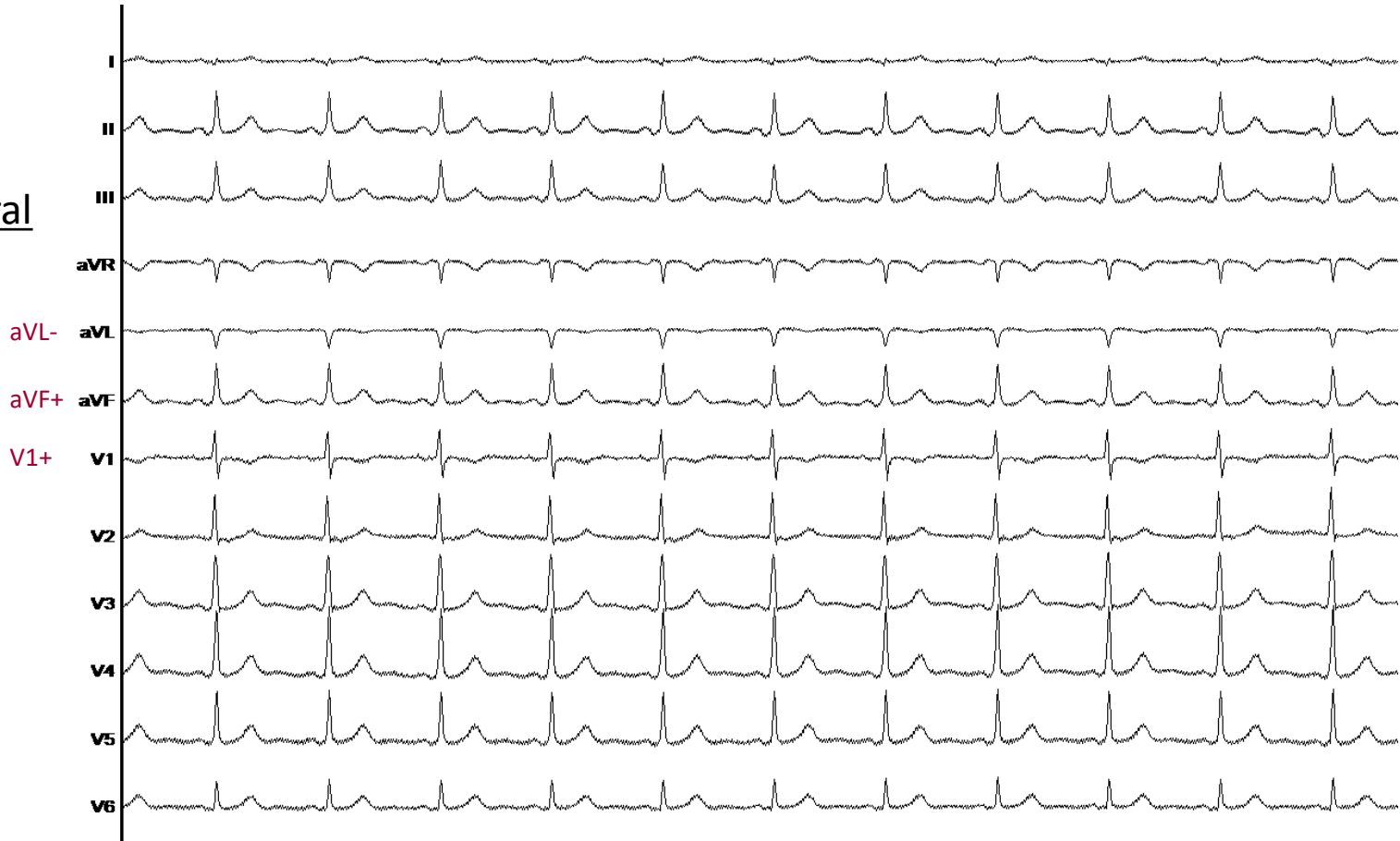
Kent latéral gauche

Dr Durand-Dubief

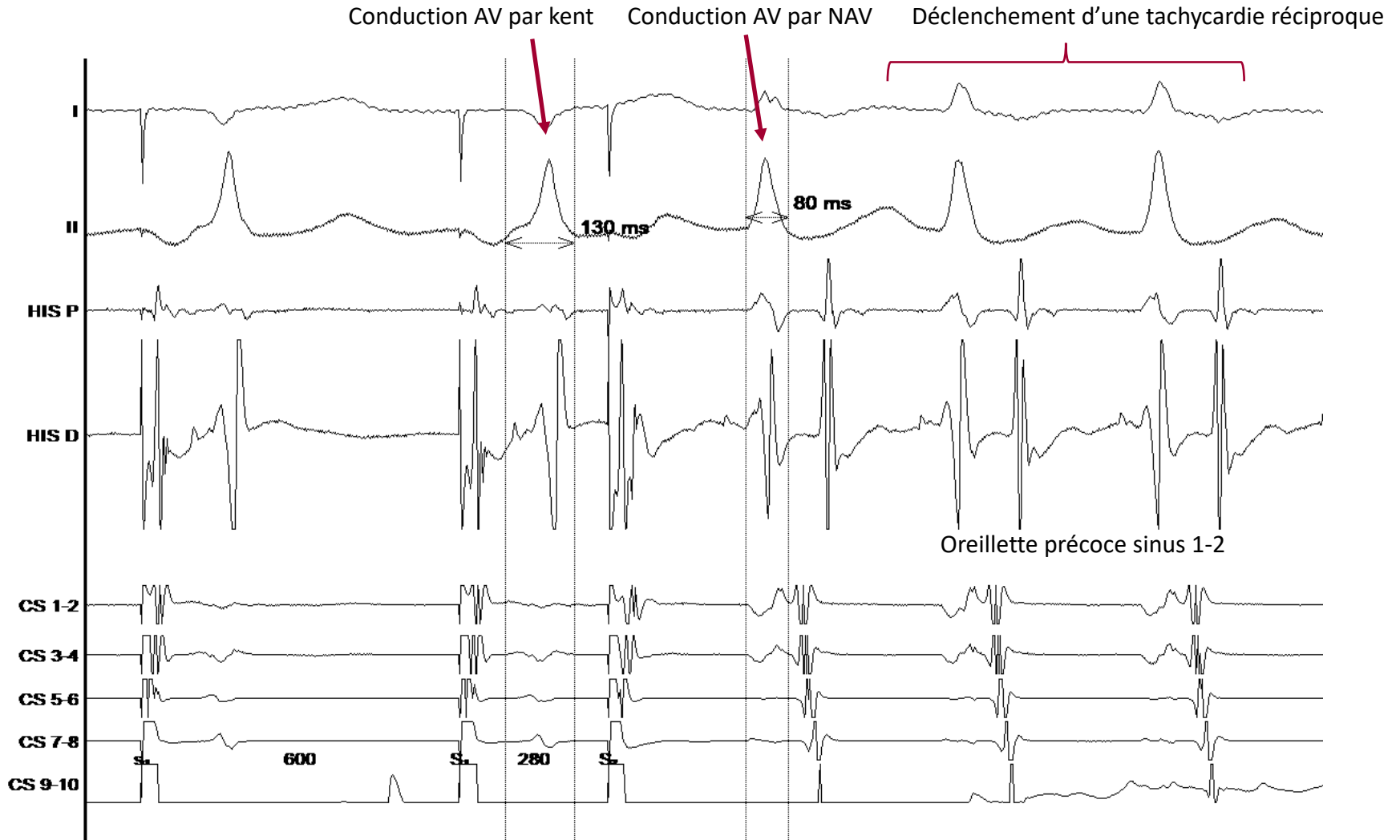
Novembre 2019 – Infirmierie Protestante

ECG de départ

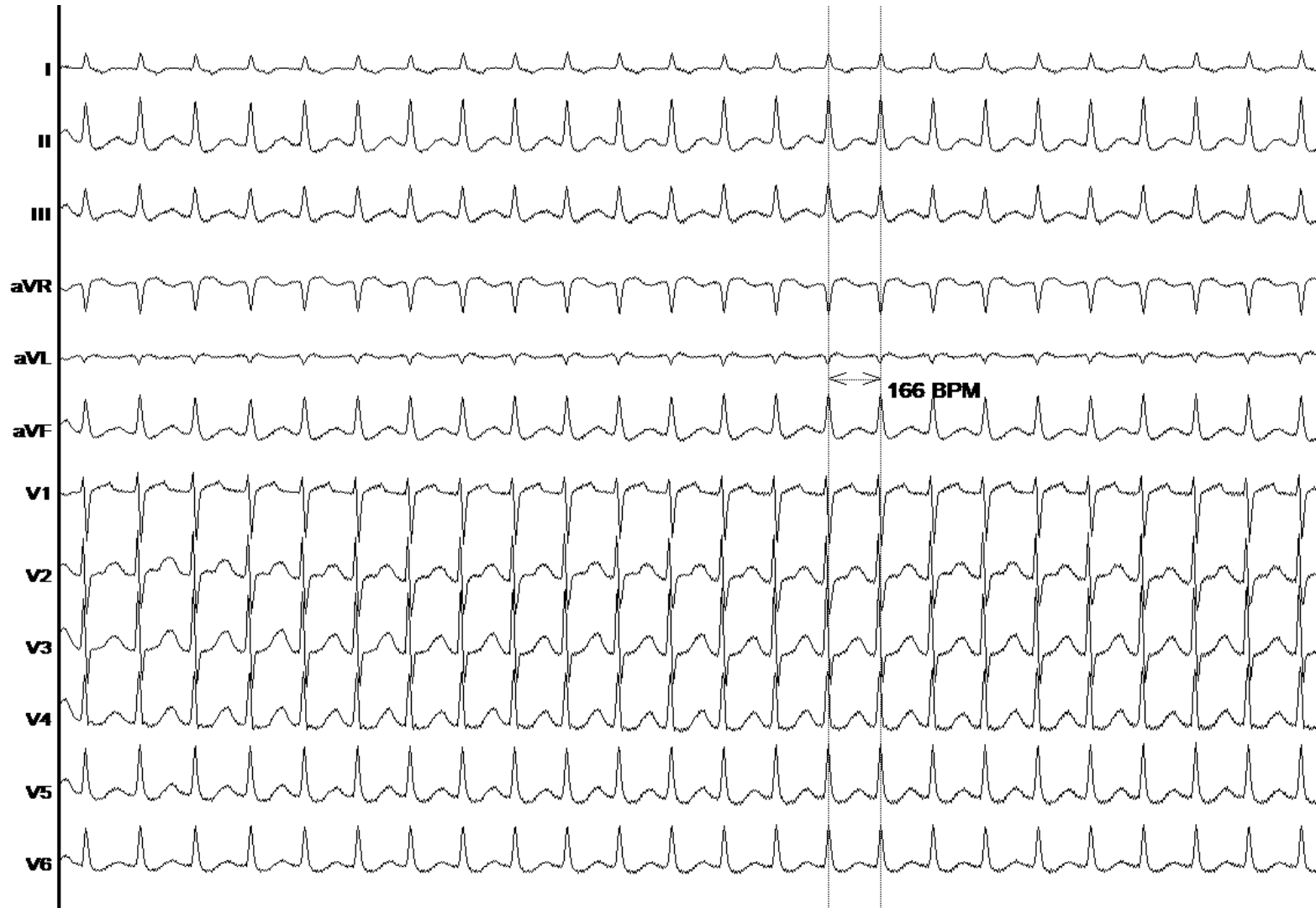
Kent latéral
gauche



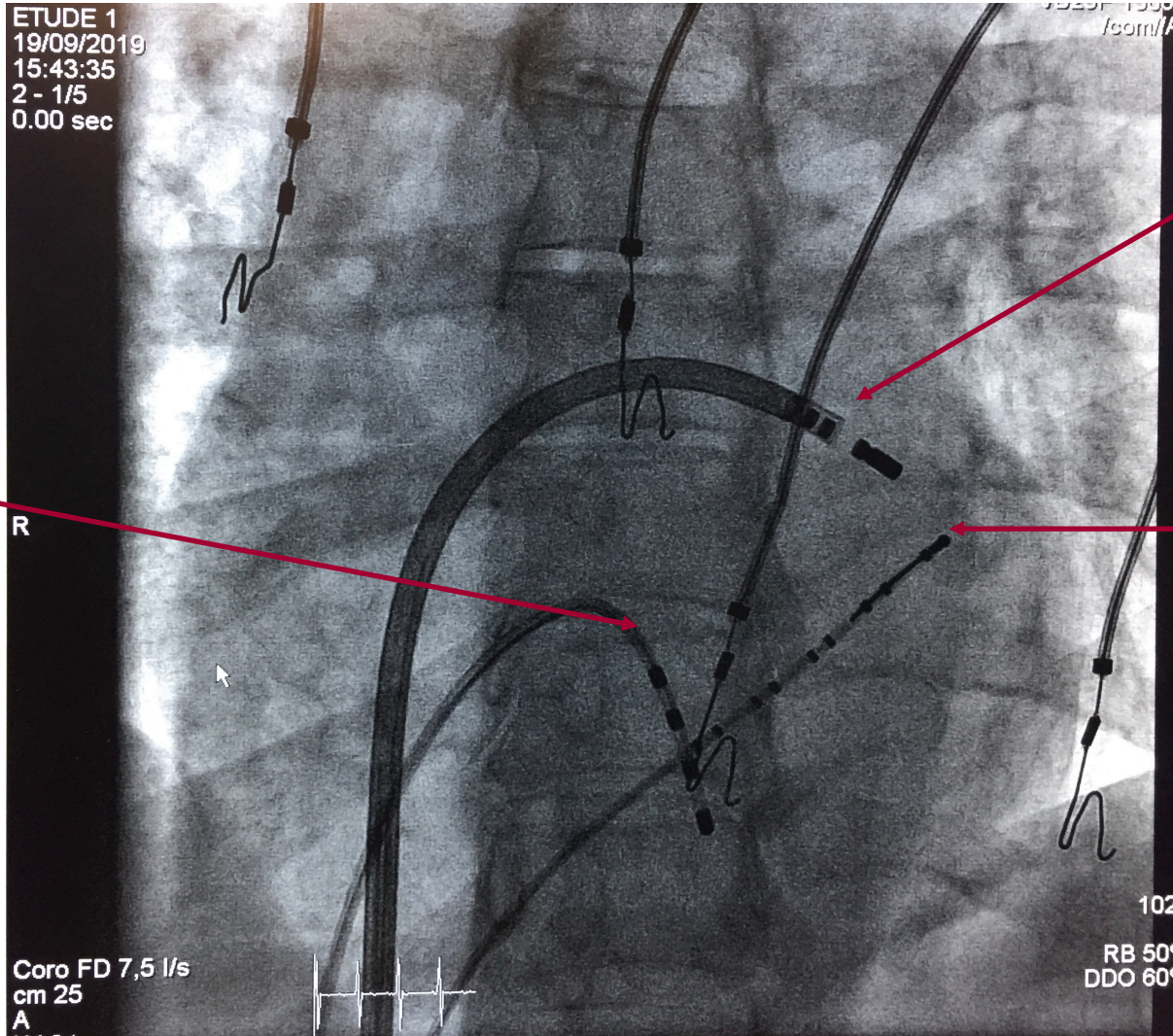
Stimulation atriale programmée



Tachycardie réciproque orthodromique



Site d'ablation

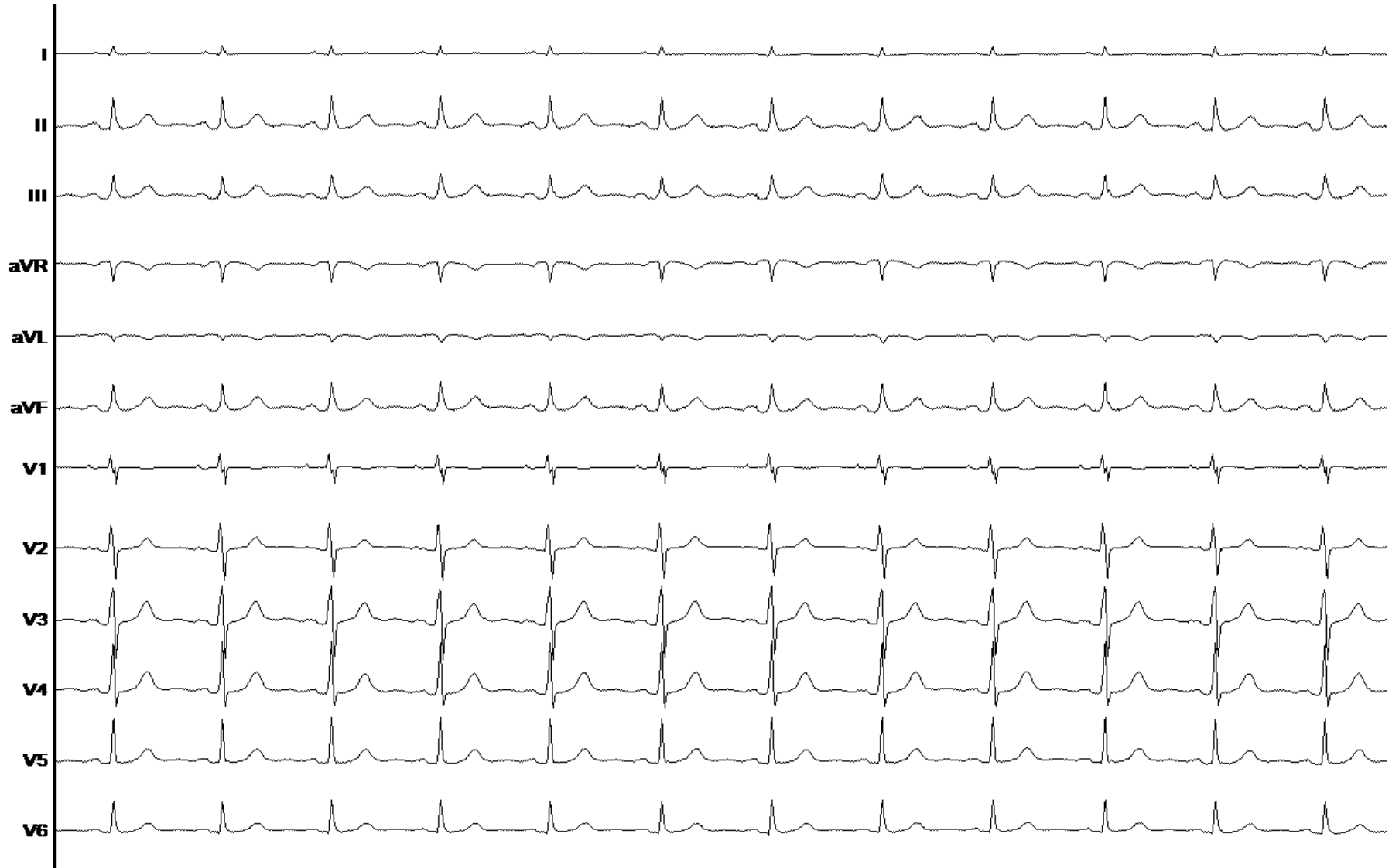


Sonde His

Sonde d'ablation

Sonde du sinus

ECG de fin



- **Stratégie**
 - Trans-septal
 - Gaine orientable + sonde irriguée
- **Matériel**
 - 4C Biotronik
 - Inquiry decapolaire Abbott
 - Agilis Abbott
 - Flexability Abbott